



PRESENTING CLINICAL SIGNS

DATE History: Previously diagnosed with stage B2 DVMD on 6/14/21. Receiving pimobendan 2.5 mg BID.

ECHOCARDIOGRAPHIC FINDINGS

2D, M-mode, and Doppler study.

PERFORMED BY:

There is mild left atrial dilation. The mitral valve leaflets are mildly thickened and exhibit systolic prolapse. There is Doppler evidence of mitral regurgitation present. There is very mild left ventricular dilation. Left ventricular systolic function is hyperdynamic. The aorta and aortic valve are normal. Right atrial and right ventricular dimensions are normal. The tricuspid valve appears normal, though trace tricuspid regurgitation is present. The pulmonary artery and pulmonic valve are normal. No shunting lesions are visualized. No pericardial effusion or cardiac masses are seen.

Jennifer Migner,
RDCS

INTERPRETED BY

Keith Blass, DVM,
MS, DACVIM
(Cardiology)

LA - 32.4 mm
LVIDd - 30.3 mm
LVIDs - 13.2 mm
FS - 56.4%
RA - 24.7 mm
LVOT - 1.54 m/s
RVOT - 1.10 m/s

PATIENT

Rocco Dinsmore

ASSESSMENT/RECOMMENDATIONS

Degenerative mitral valve disease

SPECIES

Canine

This examination demonstrates no progression of Rocco's mitral valve disease over the past 8 months. Given the presence of only mild left heart chamber dilation, Rocco's mitral valve disease appears to be well-compensated, and his current risk for the development of clinical signs secondary to it, such as coughing, exercise intolerance, syncope, and labored breathing, appears to be relatively low.

BREED

Lhasa Apso

No change in therapy is recommended based on this exam.

A recheck echocardiogram is recommended in 9 months. Thoracic radiographs are recommended if Rocco experiences respiratory clinical signs.

SEX

MN

AGE

12 y

WEIGHT

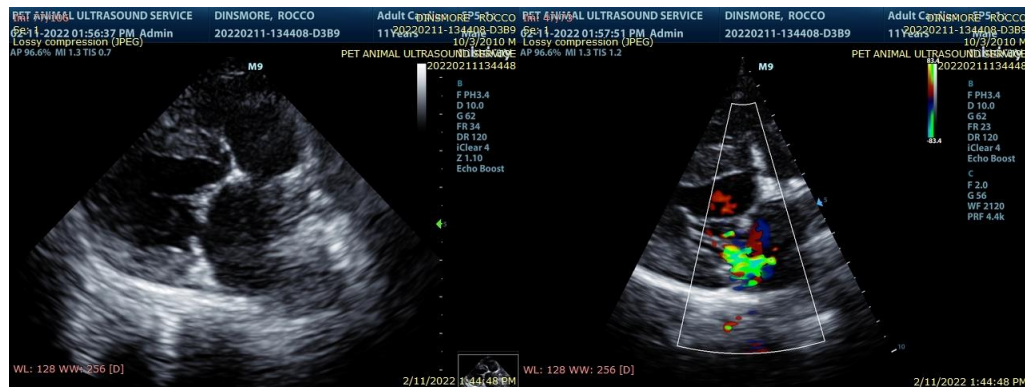
22 lb

HOSPITAL NAME

Wood River AH

REFERRING VET

Dr. Fischer



The information and recommendations provided are based on the images presented by the referring veterinarian. No evaluation can be communicated regarding pathology that was not visible in the image/video clips provided.

Thank you for this referral. If the clinical or image interpretation does not parallel your findings or if I can be of any further assistance please contact me.



DATE

2/13/22

Keith Blass, DVM, MS, DACVIM (Cardiology)
KeithBlass@gmail.com
631-804-5754

PERFORMED BY:

Jennifer Migner,
RDCS

INTERPRETED BY

Keith Blass, DVM,
MS, DACVIM
(Cardiology)

PATIENT

Rocco Dinsmore

SPECIES

Canine

BREED

Lhasa Apso

SEX

MN

AGE

12 y

WEIGHT

22 lb

HOSPITAL NAME

Wood River AH

REFERRING VET

Dr. Fischer